Original Article

Ann Coloproctol 2022 Nov 10 [Epub ahead of print]
https://doi.org/10.3393/ac.2022.00129.0018

Annals of Coloproctology

pISSN 2287-9714 eISSN 2287-9722
www.coloproctol.org

Anal canal coronal-sagittal ratio: a novel parameter for diagnosing pelvic floor injury in two-dimensional transanal ultrasound

Hong Yoon Jeong, Kee Hoon Hyun, Jong Kyun Lee
Department of Surgery, Seoul Song Do Hospital, Seoul, Korea

Purpose: Pelvic floor injury diagnosis using 3-dimensional (3D) pelvic floor ultrasound or magnetic resonance imaging is unfeasible in many clinics. We assessed the efficacy of a novel diagnostic parameter, the anal canal coronal-sagittal (CS) ratio, for pelvic floor injury on 2-dimensional [2D] transanal ultrasound.
Methods: This retrospective study analyzed the data of 126 female patients who underwent 3D pelvic floor ultrasound (including 2D transanal ultrasound) at a pelvic floor center between August and December 2020. The anal canal CS ratio on 2D transanal ultrasound and pelvic floor avulsion injury measurements were recorded for all patients.
Results: A cutoff anal canal CS ratio of 1.15 was obtained using receiver operating characteristic analysis (sensitivity, 0.820; specificity, 0.763; and area under the curve, 0.838). Patients were categorized into the anal canal CS ratio ≥ 1.15 and the anal canal CS ratio < 1.15 groups. Bilateral pelvic floor avulsion was more common in the anal canal CS ratio ≥ 1.15 group (n = 35, 56.5%), and the incidence of pelvic floor avulsion was significantly different between the 2 groups (P = 0.001). Existing parameters of pelvic floor injury, including minimal levator hiatus (P = 0.001), levator plate descent angle (P = 0.001), and levator ani deficiency score (P = 0.001), were statistically different between the 2 groups.
Conclusion: The anal canal CS ratio was an efficient novel parameter that indirectly detected pelvic floor injury in 2D transanal ultrasound. It is a potential alternative indicator for pelvic floor injury on the widely popular 2D transanal ultrasound.

Keywords: *Diagnosis; Pelvic floor disorders; Ultrasonography*

INTRODUCTION

Pelvic floor injury is prevalent in 15% to 35% of vaginally parous women [1]. Childbearing is associated with an increase in the pelvic floor morbidity, mainly due to macroscopic trauma to the levator ani muscle (LAM) and hiatal enlargement [2]. It is likely the most significant environmental factor for pelvic floor dysfunction in women. Birth-induced injury to the LAM is strongly associated with pelvic organ prolapse (POP) [3, 4] and the downward displacement of the perineal structures [5, 6]. The relationships between pelvic floor injury and fecal incontinence [7] and urinary incontinence [8] have also been evaluated. Unfortunately, the mechanism underlying the development of pelvic floor disorders due to anatomical injury to the pelvic floor is not fully understood.

Recently, 3-dimensional (3D) pelvic floor ultrasound has been widely used to evaluate pelvic floor injury, and the results are similar to those obtained by magnetic resonance imaging (MRI) [9]. In 3D pelvic floor ultrasound, the levator ani deficiency (LAD) scoring system for pelvic floor injury is used to express the specific extent and severity of LAD [10]. High LAD scores are associated with POP and other pelvic floor disorders. However, it is impossible to prepare expensive equipment, such as those for 3D pelvic floor ultrasound or MRI, in all clinics. Therefore, we at-

Received: Feb 8, 2022 • Revised: Apr 29, 2022 • Accepted: May 21, 2022
Correspondence to: Kee Hoon Hyun, M.D.
Department of Surgery, Seoul Song Do Hospital, 72 Dasan-ro, Jung-gu, Seoul 04597, Korea
Tel: +82-2-2250-7368, Fax: +82-2-2233-8528
E-mail: vishnujin84@gmail.com
ORCID: https://orcid.org/0000-0002-2385-6069

tempted to find a new transanal ultrasound parameter, which can be easily implemented in all clinics.

The LAM is commonly considered to be injured during childbirth, avulsed from its origin on the inferior pubic ramus [11]. Thus, pelvic floor injury has a marked effect on hiatal dimensions [12]. Several anatomical studies have focused on the infrastructure of the puborectalis (PR) and the external anal sphincter (EAS) complex [13]. Evidence supports the PR-EAS complex as a single entity separable from the pelvic floor muscle [14]. We hypothesize that damage to the posterior compartment, perineum, and anal sphincter due to childbirth decreases the strength to enable contractions in the pelvic floor, thereby widening the angle of the PR-EAS complex. The consequence is that both the squeezing and straining processes become difficult, which may cause pelvic floor disorders. Therefore, measurement of the extent of the PR-EAS complex in a transanal ultrasound will not only allow a radiological diagnosis, but also an evaluation of the physiological function.

We developed a new parameter, the anal canal coronal-sagittal (CS) ratio, which could easily measure the extent of the PR-EAS complex during transanal ultrasound. The objective of the current study was to define the efficacy of assessment of pelvic floor injury using this novel diagnostic parameter during 2-dimensional (2D) transanal ultrasound.

METHODS

This was a retrospective study performed at a pelvic floor center using data obtained between August 2020 and December 2020. Patients who underwent fistula or hemorrhoid surgery with sphincter injury were excluded. This study was performed in compliance with the principles of the Declaration of Helsinki, and its protocol was reviewed and approved by our Institutional Review Board (No. 2021-02). Informed consent was waived because of the retrospective nature of the study.

All consecutive patients who underwent 3D pelvic floor ultrasound by a single examiner during the study period were included in the study. A total of 126 patients underwent 3D pelvic floor ultrasound (including 2D transanal ultrasound) performed by an experienced pelvic floor surgeon. The examination was conducted using a 3D ultrasound device (Flex Focus, endoprobe model 8838; B-K Medical, Herlev, Denmark). The ultrasound was performed in the modified lithotomy position and immediately after voiding. The images were acquired according to the 5 steps reported by Shobeiri et al. [15]. These images comprised transperineal 2D functional images, endovaginal functional 2D images, endovaginal 3D images, and endoanal 3D images. Images with partially invisible sections of the levator plate were not used. The patients were observed for pelvic floor symptoms, such as fecal incontinence, constipation, and urinary incontinence. Our assessment included a medical history examination and questionnaires for constipation and fecal incontinence. The preoperative questionnaire included the Cleveland Clinic Constipation Scoring System (Wexner constipation score), Cleveland Clinic Incontinence Score (Wexner incontinence score), Fecal Incontinence Severity Index, and Fecal Incontinence Quality of Life (FIQL) scale [16, 17]. All pelvic floor disorders were diagnosed based on the American Society of Colon and Rectum Surgeons' guidelines [18]. All patients underwent manometry, electromyography (EMG), and pudendal nerve terminal motor latency (PNTML) tests.

In all cases, 3D pelvic floor ultrasound was performed for the LAD score, levator plate descent angle (LPDA), and minimal levator hiatus (MLH). According to previous studies, these 3D pelvic floor ultrasound parameters are associated with pelvic floor injury. The LAD scoring system provided scores from 0 to 18 points according to the definition set by Morgan et al. [8]. Furthermore, the LPDA (defined by Rostaminia et al. [10]) for the midsagittal view was measured in all patients. We also performed detailed measurements of the MLH, which was recently described by Shobeiri et al. [19], using 3D endovaginal ultrasound (EVUS). Cases with incomplete data (including scores for incontinence and constipation) or poor-quality ultrasound scans were excluded. The anal sphincter injury was measured using endoanal 3D images.

Definition of the anal canal coronal-sagittal ratio

The U-shaped PR muscle can be clearly identified in the upper canal on transanal ultrasound (Fig. 1A). Down in the mid-canal,

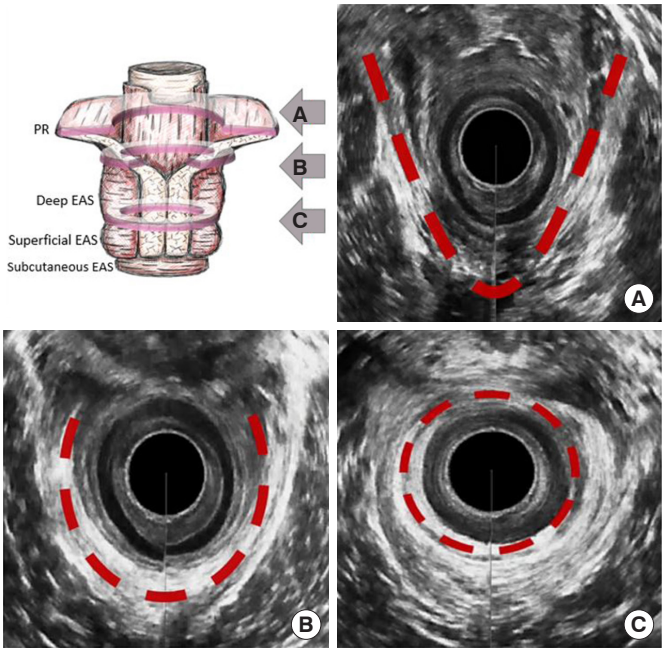

Fig. 1. Measuring position of the anal canal coronal-sagittal ratio on a transanal ultrasound. (A) U-shaped PR muscle, (B) inverted omega-shaped PR-EAS complex, and (C) circular-shaped EAS. EAS, external anal sphincter; PR, puborectalis.

the PR-EAS complex is formed (Fig. 1B), after which a circular EAS is formed (Fig. 1C). We selected the location where the U-shaped PR muscle (with high echogenicity) became an inverted omega-shaped PR-EAS complex as the measurement standard. In other words, the starting position of the PR-EAS complex was used as a reference. As shown in Fig. 2, a straight line connecting both ends of the PR-EAS complex was defined as the coronal line (C-line, mm). A line drawn vertically down the C-line to the posterior internal anal sphincter was called the sagittal line (S-line, mm). The value obtained by dividing the C-line by the S-line was defined as the anal canal CS ratio (anal canal CS ratio = C-line/S-line). The larger the pelvic floor injury, the larger the C-line value and higher the anal canal CS ratio. Therefore, the cutoff value was determined based on an LAD score of more than 12 points (severe LAD).

Statistical analyses

Using receiver operating characteristic (ROC) statistics, a compromise between avoiding false negatives and optimizing true positives suggested a cutoff for the anal canal CS ratio. All patients were classified according to their anal canal CS ratio into the anal canal CS ratio <1.15 group or the anal canal CS ratio ≥ 1.15 group. Categorical variables are expressed as numbers and percentages. Continuous variables were assessed for normality using the Shapiro-Wilk test and are expressed as mean and standard deviation. To determine the differences in the patient characteristics, physiological test results, and 3D pelvic floor ultrasound results between the 2 groups, we used an analysis of variance for continuous data and the Student t-test for noncontinuous data. All statistical analyses were performed using the IBM SPSS Statistics ver. 22.0 (IBM Corp., Armonk, NY, USA).

RESULTS

A total of 126 female patients who underwent 3D pelvic floor ultrasound (including 2D transanal ultrasound) and physiological examinations were included in the study. Fig. 3 shows the ROC curve-based optimal cutoff value of the anal canal CS ratio for predicting severe LAD on transanal ultrasound. An identical cutoff for an anal canal CS ratio of 1.15 was obtained with ROC statistics, with an improved sensitivity (0.820) and specificity (0.763) and an area under the curve of 0.838 (Fig. 3).

Sixty-four patients comprised the anal canal CS ratio <1.15 group (50.8%), while 62 patients comprised the anal canal CS ratio ≥ 1.15 group (49.2%); there were no significant differences in the age (63.59 ± 12.21 years vs. 65.24 ± 12.39 years, $P = 0.453$) and parity (2.33 vs. 2.58, $P = 0.233$) between the 2 groups. There was no significant intergroup difference in the number of patients with previous surgeries, such as hysterectomy and the tension-free vaginal tape procedure. The proportion of patients who underwent a normal spontaneous vaginal delivery was significantly higher in the anal canal CS ratio ≥ 1.15 group than in the anal canal CS ratio <1.15 group (93.5% vs. 82.8%, $P = 0.033$). Regarding pelvic floor symptoms, mixed symptoms (both incontinence and constipation symptoms) and constipation were common in the anal canal CS ratio ≥ 1.15 group (37.1%) and the anal canal CS ratio <1.15 (37.5%) group, respectively; however, their incidence did not differ significantly. In the anal canal CS ratio ≥ 1.15 group, the scores for the symptoms of incontinence and constipation increased, while the quality of life worsened. The FIQL scores significantly differed between the anal canal CS ratio <1.15 group and the anal canal CS ratio ≥ 1.15 group (13.80 ± 3.81 vs. 11.91 ± 4.35, $P = 0.044$) (Table 1). The results of manometry, EMG, and PNTML are summarized in Table 2. The maximal

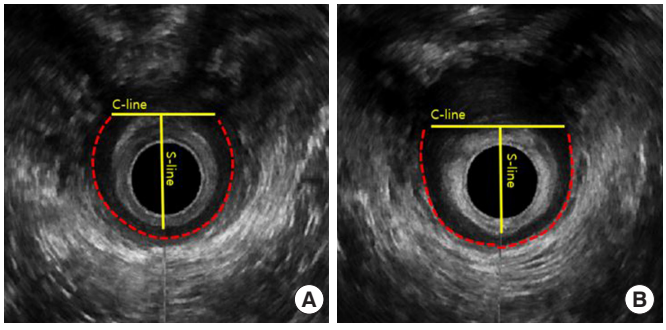

Fig. 2. Anal canal coronal-sagittal (CS) ratio under transanal ultrasound. (A) Anal canal CS ratio <1.15 image. (B) Anal canal CS ratio ≥ 1.15 image. C-line, coronal line; S-line, sagittal line.

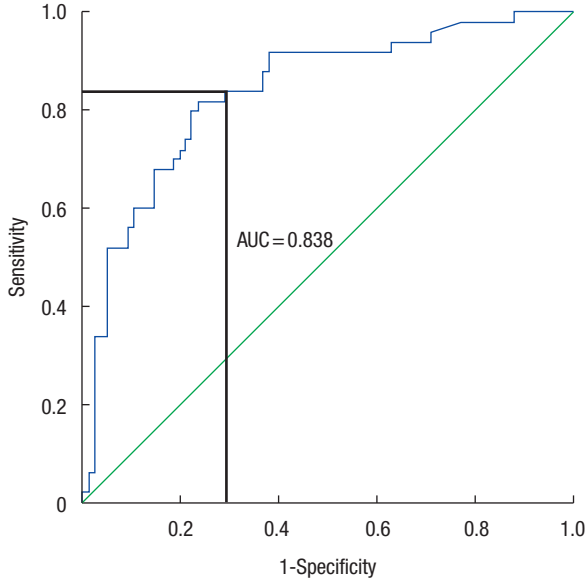

Fig. 3. Receiver operating characteristic curve showing optimal cutoff for anal canal coronal-sagittal ratio to predict severe levator ani deficiency (n = 26). Sensitivity, 0.820 and specificity, 0.763; area under the curve (AUC) 0.838.

Table 1. Patients' demographics

Characteristic	AC-CS ratio		P-value
	<1.15	≥1.15	
No. of patients	64	62	
Age (yr)	63.59±12.21	65.24±12.39	0.453
No. of parity	2.33 (1–6)	2.58 (1–9)	0.233
Type of delivery			
Normal spontaneous vaginal delivery	53 (82.8)	58 (93.5)	
Cesarean section	9 (14.1)	1 (1.6)	0.033
Both types of parity	2 (3.1)	3 (4.8)	
Urinary Incontinence	27 (42.2)	31 (50.0)	0.475
Posterior pelvic floor symptom			
Incontinence	24 (37.5)	22 (35.5)	
Constipation	24 (37.5)	17 (27.4)	0.285
Mixed symptom[a]	16 (25.0)	23 (37.1)	
Previous operation			
Hysterectomy	6 (9.4)	9 (14.5)	0.420
Tension-free vaginal tape	8 (12.5)	10 (16.1)	0.617
Incontinence score			
CCIS	7.32±5.48	8.86±6.15	0.248
FIQL	13.80±3.81	11.91±4.35	0.044
FISI	21.41±15.51	28.07±16.77	0.072
Constipation score, CCCS	9.68±7.01	10.14±5.13	0.748

Values are presented as number only, mean±standard deviation, mean (range), or number (%).
AC, anal canal; CS, coronal-sagittal; CCIS, Cleveland Clinic Incontinence Score; FIQL, Fecal Incontinence Quality of Life; FISI, Fecal Incontinence Severity Index; CCCS, Cleveland Clinic Constipation Score.
[a]Mixed symptom: Both incontinence symptom and constipation symptom.

squeezing pressure was significantly lower in the anal canal CS ratio ≥1.15 group than in the anal canal CS ratio <1.15 group (118.73±57.66 mmHg vs. 96.71±50.78 mmHg, P=0.025). There were no differences between the 2 groups in terms of the maximal resting pressure, EMG, and PNTML.

The 3D pelvic floor ultrasound results are shown in Table 3. All pelvic floor disorders, including rectocele, were more common in the anal canal CS ratio ≥1.15 group as compared to in the anal canal CS ratio <1.15 group. In particular, the incidence of cystocele was significantly different between the anal canal CS ratio <1.15 group and the anal canal CS ratio ≥1.15 group (18.8% vs. 37.1%, P=0.029). Bilateral pelvic floor avulsion was more common in the anal canal CS ratio ≥1.15, group (n=35, 56.5%), and the incidence of pelvic floor avulsion was significantly different between the 2 groups (P=0.001). Furthermore, there was a significant difference in the incidence of anal sphincter injury between the anal canal CS ratio <1.15 group and the anal canal CS ratio ≥1.15 group (15.6% vs. 54.8%, P=0.001). The existing parameters for pelvic floor injury, including the MLH (15.18±2.40 cm^2 vs. 17.49±2.84 cm^2, P=0.001), LPDA (9.29°±5.91° vs. 2.43°±6.67°, P=0.001), and the LAD score (8.08±3.73 vs. 12.84±3.21, P=0.001), were significantly different between the anal canal CS ratio <1.15 group and the anal canal CS ratio ≥1.15 group.

Table 2. Physiological tests

Variable	AC-CS ratio		P-value
	<1.15	<1.15	
Maximal resting pressure (mmHg)	54.73±17.86	52.29±15.94	0.422
Maximal squeezing pressure (mmHg)	118.73±57.66	96.71±50.78	0.025
Electromyography			
Normal movement	27 (42.2)	23 (37.1)	
Paradoxical movement	27 (42.2)	34 (54.8)	0.252
Equivocal movement	10 (15.6)	5 (8.1)	
PNTML			
Normal	45 (70.3)	41 (66.1)	
Unilateral latency	15 (23.4)	12 (19.4)	0.299
Bilateral latency	4 (6.3)	9 (14.5)	

Values are presented as mean±standard deviation or number (%).
AC, anal canal; CS, coronal-sagittal; PNTML, pudendal nerve terminal motor latency.

Table 3. Pelvic floor disorders and parameters of pelvic floor injury on 3-dimensional pelvic floor ultrasound

Variable	AC-CS ratio		P-value
	<1.15	<1.15	
Pelvic floor disorder			
Rectocele	35 (54.7)	42 (67.7)	0.147
Cystocele	12 (18.8)	23 (37.1)	0.029
Enterocele	1 (1.6)	3 (4.8)	0.361
Internal intussusception	33 (51.6)	40 (64.5)	0.153
Anismus	24 (37.5)	21 (33.9)	0.713
Pelvic floor avulsion			
No avulsion	23 (35.9)	4 (6.5)	
Unilateral avulsion	31 (48.5)	23 (37.1)	0.001
Bilateral avulsion	10 (15.6)	35 (56.5)	
Minimal levator hiatus (cm^2)	15.18±2.40	17.49±2.84	0.001
Levator plate descent angle (°)	9.29±5.91	2.43±6.67	0.001
Levator ani deficiency score	8.08±3.73	12.84±3.21	0.001
Anal sphincter injury	10 (15.6)	34 (54.8)	0.001

Values are presented as number (%) or mean±standard deviation.
AC, anal canal; CS, coronal-sagittal.

DISCUSSION

Our data demonstrated that a new parameter, the anal canal CS ratio, indirectly indicated pelvic floor injury on 2D transanal ultrasound. We not only presented a new method for diagnosing pelvic floor injury, but also its cutoff value. In the LAD scoring system defined by Morgan et al. [8], the cutoff value for the anal canal CS ratio was calculated according to the severe LAD score. Because of our hypothesis that pelvic floor injury leads to anatomical changes in the PR-EAS complex in the anal canal, we used a severe LAD score in the anal canal CS ratio. Previous studies have shown that minor LAM avulsion behaved similarly to no LAM avulsion [20]. Therefore, severe LAD, which can be referred to as major LAM avulsion, was used as the diagnostic standard. The optimal cutoff value of the anal canal CS ratio obtained from our data was 1.15; its sensitivity and specificity were 82.0% and 76.3%, respectively. We expect that both the sensitivity and specificity will improve with the inclusion of larger sample sizes in future studies.

The association of LAM injuries with prolapse and impaired pelvic floor muscle function is consistent with the findings of previous studies concerning the LAM structure and electrophysiology [21, 22]. In addition, the activity of LAM automatically adjusts to variations in posture and abdominal pressure to provide upward support to the pelvic viscera [23, 24]. Therefore, previous studies have suggested that LAM injury is associated with symptoms of pelvic floor disorders, such as constipation, incontinence, and POP [3, 7, 8]. Our data showed that the FIQL and Wexner constipation scores were significantly different between the 2 groups. The symptoms of pelvic floor disorders were more severe in the anal canal CS ratio ≥1.15 group with severe LAM injury. However, no difference in the incidence of urinary incontinence was observed between the 2 groups, because the evaluation was not conducted through an objective questionnaire. Our other hypothesis is that LAM injury leads to an increase in the PR-EAS complex angle, which in turn leads to a decrease in the physiological function. Shafik et al. [14] explained that the EAS is separated from the PR-EAS complex by receiving muscle fibers. Interestingly, in our data, the maximal squeezing pressure was significantly lower in the anal canal CS ratio ≥1.15 group, because LAM injury causes damage to the PR-EAS complex, which degrades the physiological functioning of the EAS. Therefore, anatomical injury to the pelvic floor is associated with a decrease in the physiological function and an aggravation of the pelvic floor symptoms.

Injury to the pelvic floor muscles as a result of childbirth has been documented [25]. In our patients, the rate of vaginal delivery was significantly higher in the group with a large anal canal CS ratio. LAM birth-related injuries can be detected using modern imaging techniques, such as MRI [26] and 3D pelvic floor ultrasound [27]. Recently, several indicators for LAM injury in 3D pelvic floor ultrasound, including the MLH, LPDA, and LAD score, have been introduced. Shobeiri et al. [19] reported that the normal range of the MLH area and LPDA in healthy nulliparous women (median age, 47 years) were 13.6 cm^2 and 15.9°, respectively. The patients included in our study were parous women with pelvic floor symptoms, resulting in larger MLH and smaller LPDA values. In this study, when the anal canal CS ratio was ≥1.15, the MLH and LPDA indicating pelvic floor injury on 3D pelvic floor ultrasound were significantly different. Therefore, the anal canal CS ratio using 2D transanal ultrasound effectively identified LAM injury. Several studies have demonstrated that the relationship between pelvic floor disorders and LAM injury is unclear [28]. In our study, although there were no significant differences between the 2 groups, the incidence of all pelvic floor disorders was higher in the anal canal CS ratio ≥1.15 group with a large LAM injury. The incidence of cystocele differed significantly between the 2 groups due to enlargement of the urogenital hiatus secondary to PR widening. The relationship between LAM injury and pelvic floor disorders requires further study. Although 3D pelvic floor ultrasound provides a lot of information about LAM injury, it is difficult to distribute equipment to most clinics. The anal canal CS ratio is a method that can reproduce LAM injury findings on 3D pelvic floor ultrasound with the use of 2D transanal ultrasound.

We focused on ratio, and not the length and area, because the size and shape of the anal canal vary among individuals. The increase in the anal canal CS ratio was due to an increase in the length of the C-line. In patients with a large LAM injury, the change in the C-line length was more dramatic than the change in the S-line length. This change occurs because of anatomical changes in the LAM during childbirth. The PR muscle is commonly considered to experience injury during vaginal delivery, due to avulsion from insertion into the pubic ramus [11, 29]. In addition, recent studies using 3D EVUS have found that hematoma during the first childbirth can also be a reason for LAM injury [30]. Avulsion of muscles from the pubic ramus is known to have a marked effect on the LAM dimensions [31]. Eventually, the increase in the LAM dimension causes an increase in the size of the MLH in 3D pelvic floor ultrasound and an increase in the anal canal CS ratio in 2D transanal ultrasound. In other words, the anal canal CS ratio reflects the widened angle of the PR muscle due to injury of the PR-EAS complex and LAM. Then, we considered where the PR widening was best shown and where it was the easiest to measure. We focused on the formation of a circular EAS after muscle fibers emerged from the LAM to form the PR-EAS complex. This part is where the existing U-shaped PR muscle shape changes, and it represents the section before it changes to a circular EAS. We determined that this part was the easiest location for measuring the PR-EAS complex widening and could well represent anatomical injury and physiological dysfunction of the pelvic floor.

The important finding of this study is that patients who should be recommended treatment at a pelvic floor center can be identi-

fied using 2D transanal ultrasound, which is widely used in clinics. The anal canal CS ratio will facilitate access to pelvic floor disorders to more clinics and clinicians than the current modalities. A strength of this study was the development of a method that indirectly predicted pelvic floor injury using a novel parameter in 2D transanal ultrasound. It was also found that the widening of the PR muscle angle due to LAM injury affected pelvic floor symptoms and physiological function. Iatrogenic injury to the anal sphincter and LAM due to a previous operation was excluded from the analysis, and the focus was on LAM injury caused by childbirth. We attempted to make the evaluation of pelvic floor disorders easier for many clinicians by suggesting a cutoff value of ≥1.15 for the anal canal CS ratio. Although LAM avulsion could be diagnosed through 2D transvaginal ultrasound in previous studies [32], simultaneous 2D transanal ultrasound and transvaginal ultrasound increase the patient's unpleasantness, examination time, and costs.

This study has several limitations. First, the number of patients participating in the study was 126, which is a small sample size. To obtain a more meaningful cutoff value, more patients should be included in future studies. Second, this study used results from a single examiner. Future research is needed to determine the interobserver and intraobserver agreement. Finally, the anal canal CS ratio could not be confirmed in patients without a pelvic floor injury. However, we sub-analyzed the anal canal CS ratio in 20 patients without childbirth. These patients were women aged between 20 and 29 years who visited our hospital for an anal disease and had no pelvic floor symptoms or anal sphincter injury. The mean anal canal CS ratio of these 20 patients was measured to be 1.05±0.75. Because transvaginal ultrasound could not be performed in nulliparous women due to a cultural problem in East Asia, we could not measure the LAD score in these patients; however, it was confirmed that the anal canal CS ratio was lower in young women without childbirth. In conclusion, the anal canal CS ratio was an efficient parameter that indirectly detected pelvic floor injury during 2D transanal ultrasound. This novel parameter is an alternative indicator for easily predicting pelvic floor injury using only 2D transanal ultrasound, which is widely used across clinics. This parameter may be helpful in the differential diagnosis of patients with pelvic floor injuries in clinics with limited equipment.

CONFLICT OF INTEREST

No potential conflict of interest relevant to this article was reported.

FUNDING

None.

REFERENCES

1. Krofta L, Otcenásek M, Kasíková E, Feyereisl J. Pubococcygeus-puborectalis trauma after forceps delivery: evaluation of the levator ani muscle with 3D/4D ultrasound. Int Urogynecol J Pelvic Floor Dysfunct 2009;20:1175-81.
2. Dietz HP, Simpson JM. Does delayed child-bearing increase the risk of levator injury in labour? Aust N Z J Obstet Gynaecol 2007;47:491-5.
3. DeLancey JO, Morgan DM, Fenner DE, Kearney R, Guire K, Miller JM, et al. Comparison of levator ani muscle defects and function in women with and without pelvic organ prolapse. Obstet Gynecol 2007;109(2 Pt 1):295-302.
4. Dietz HP, Simpson JM. Levator trauma is associated with pelvic organ prolapse. BJOG 2008;115:979-84.
5. Clark NA, Brincat CA, Yousuf AA, Delancey JO. Levator defects affect perineal position independently of prolapse status. Am J Obstet Gynecol 2010;203:595.e17-22.
6. DeLancey JO, Sørensen HC, Lewicky-Gaupp C, Smith TM. Comparison of the puborectal muscle on MRI in women with POP and levator ani defects with those with normal support and no defect. Int Urogynecol J 2012;23:73-7.
7. Lewicky-Gaupp C, Brincat C, Yousuf A, Patel DA, Delancey JO, Fenner DE. Fecal incontinence in older women: are levator ani defects a factor? Am J Obstet Gynecol 2010;202:491.e1-6.
8. Morgan DM, Cardoza P, Guire K, Fenner DE, DeLancey JO. Levator ani defect status and lower urinary tract symptoms in women with pelvic organ prolapse. Int Urogynecol J 2010;21:47-52.
9. DeLancey JO. The hidden epidemic of pelvic floor dysfunction: achievable goals for improved prevention and treatment. Am J Obstet Gynecol 2005;192:1488-95.
10. Rostaminia G, White D, Hegde A, Quiroz LH, Davila GW, Shobeiri SA. Levator ani deficiency and pelvic organ prolapse severity. Obstet Gynecol 2013;121:1017-24.
11. Kearney R, Miller JM, Ashton-Miller JA, DeLancey JO. Obstetric factors associated with levator ani muscle injury after vaginal birth. Obstet Gynecol 2006;107:144-9.
12. Rees CE, Knight LV. The trouble with assessing students' professionalism: theoretical insights from sociocognitive psychology. Acad Med 2007;82:46-50.
13. Shafik A. A new concept of the anatomy of the anal sphincter mechanism and the physiology of defecation. VIII. Levator hiatus and tunnel: anatomy and function. Dis Colon Rectum 1979;22:539-49.
14. Shafik A. New concept of the anatomy of the anal sphincter mechanism and the physiology of defecation. II. Anatomy of the levator ani muscle with special reference to puborectalis. Invest Urol 1975;13:175-82.
15. Shobeiri SA, LeClaire E, Nihira MA, Quiroz LH, O'Donoghue D. Appearance of the levator ani muscle subdivisions in endovaginal three-dimensional ultrasonography. Obstet Gynecol 2009;114:66-72.

16. Agachan F, Chen T, Pfeifer J, Reissman P, Wexner SD. A constipation scoring system to simplify evaluation and management of constipated patients. Dis Colon Rectum 1996;39:681-5.
17. Rockwood TH, Church JM, Fleshman JW, Kane RL, Mavrantonis C, Thorson AG, et al. Fecal Incontinence Quality of Life Scale: quality of life instrument for patients with fecal incontinence. Dis Colon Rectum 2000;43:9-16.
18. Bordeianou LG, Carmichael JC, Paquette IM, Wexner S, Hull TL, Bernstein M, et al. Consensus statement of definitions for anorectal physiology testing and pelvic floor terminology (revised). Dis Colon Rectum 2018;61:421-7.
19. Shobeiri SA, Rostaminia G, White D, Quiroz LH. The determinants of minimal levator hiatus and their relationship to the puborectalis muscle and the levator plate. BJOG 2013;120:205-11.
20. Dietz HP, Bernardo MJ, Kirby A, Shek KL. Minimal criteria for the diagnosis of avulsion of the puborectalis muscle by tomographic ultrasound. Int Urogynecol J 2011;22:699-704.
21. Boreham MK, Wai CY, Miller RT, Schaffer JI, Word RA. Morphometric properties of the posterior vaginal wall in women with pelvic organ prolapse. Am J Obstet Gynecol 2002;187:1501-8.
22. Weidner AC, Barber MD, Visco AG, Bump RC, Sanders DB. Pelvic muscle electromyography of levator ani and external anal sphincter in nulliparous women and women with pelvic floor dysfunction. Am J Obstet Gynecol 2000;183:1390-9.
23. Morgan DM, Kaur G, Hsu Y, Fenner DE, Guire K, Miller J, et al. Does vaginal closure force differ in the supine and standing positions? Am J Obstet Gynecol 2005;192:1722-8.
24. Shafik A, Doss S, Asaad S. Etiology of the resting myoelectric activity of the levator ani muscle: physioanatomic study with a new theory. World J Surg 2003;27:309-14.
25. DeLancey JO, Kearney R, Chou Q, Speights S, Binno S. The appearance of levator ani muscle abnormalities in magnetic resonance images after vaginal delivery. Obstet Gynecol 2003;101:46-53.
26. Branham V, Thomas J, Jaffe T, Crockett M, South M, Jamison M, et al. Levator ani abnormality 6 weeks after delivery persists at 6 months. Am J Obstet Gynecol 2007;197:65.e1-6.
27. Santoro GA, Wieczorek AP, Dietz HP, Mellgren A, Sultan AH, Shobeiri SA, et al. State of the art: an integrated approach to pelvic floor ultrasonography. Ultrasound Obstet Gynecol 2011;37:381-96.
28. Handa VL, Blomquist JL, Roem J, Muñoz A, Dietz HP. Pelvic floor disorders after obstetric avulsion of the levator ani muscle. Female Pelvic Med Reconstr Surg 2019;25:3-7.
29. Shek KL, Dietz HP. Intrapartum risk factors for levator trauma. BJOG 2010;117:1485-92.
30. van Delft K, Thakar R, Shobeiri SA, Sultan AH. Levator hematoma at the attachment zone as an early marker for levator ani muscle avulsion. Ultrasound Obstet Gynecol 2014;43:210-7.
31. Otcenasek M, Krofta L, Baca V, Grill R, Kucera E, Herman H, et al. Bilateral avulsion of the puborectal muscle: magnetic resonance imaging-based three-dimensional reconstruction and comparison with a model of a healthy nulliparous woman. Ultrasound Obstet Gynecol 2007;29:692-6.
32. van Delft KW, Sultan AH, Thakar R, Shobeiri SA, Kluivers KB. Agreement between palpation and transperineal and endovaginal ultrasound in the diagnosis of levator ani avulsion. Int Urogynecol J 2015;26:33-9.