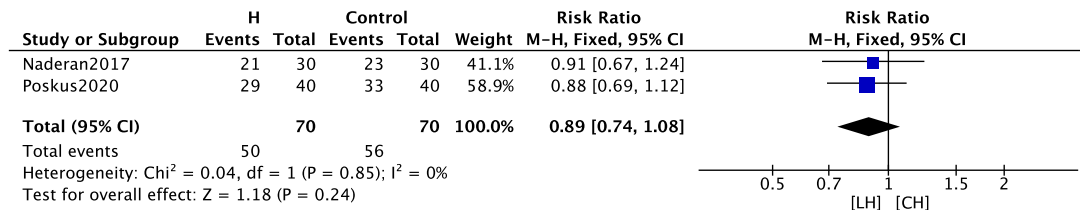
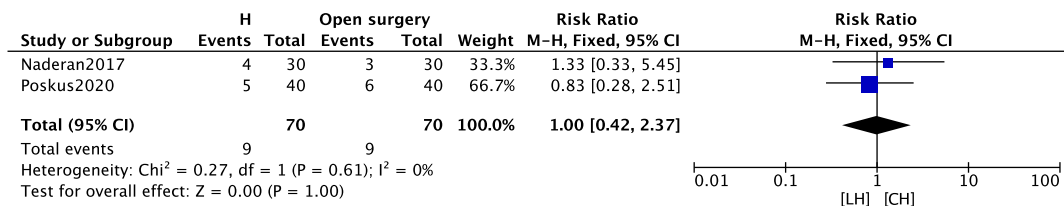


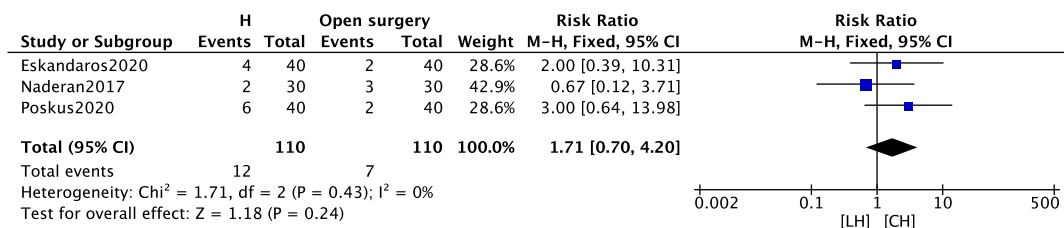
**Supplementary Fig. 7.** Visual analogue scale scores of postoperative day 7. SD, standard deviation; IV, intravital; CI, confidence interval; df, degree of freedom. LH, laser hemorrhoidoplasty; CH, conventional hemorrhoidectomy.



**Supplementary Fig. 8.** Twelve-month symptom free. CI, confidence interval; df, degree of freedom. LH, laser hemorrhoidoplasty; CH, conventional hemorrhoidectomy.



**Supplementary Fig. 9.** Twelve-month risk of bleeding. CI, confidence interval; df, degree of freedom. LH, laser hemorrhoidoplasty; CH, conventional hemorrhoidectomy.



**Supplementary Fig. 10.** Twelve-month risk of prolapse. CI, confidence interval; df, degree of freedom. LH, laser hemorrhoidoplasty; CH, conventional hemorrhoidectomy.