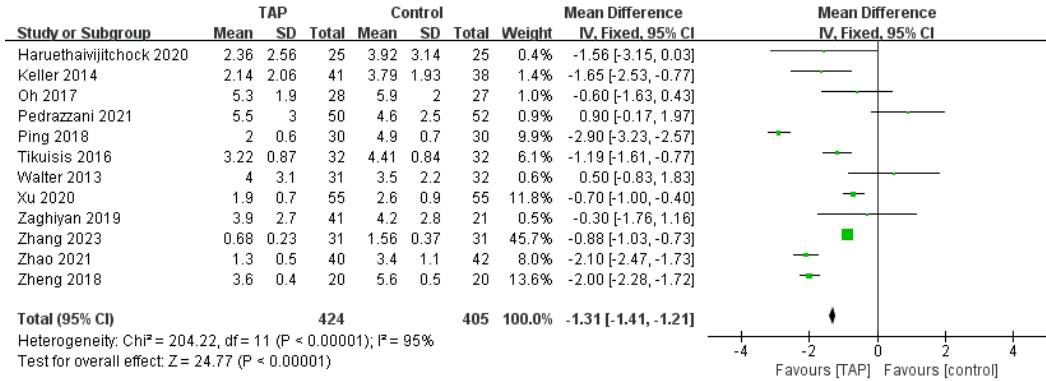
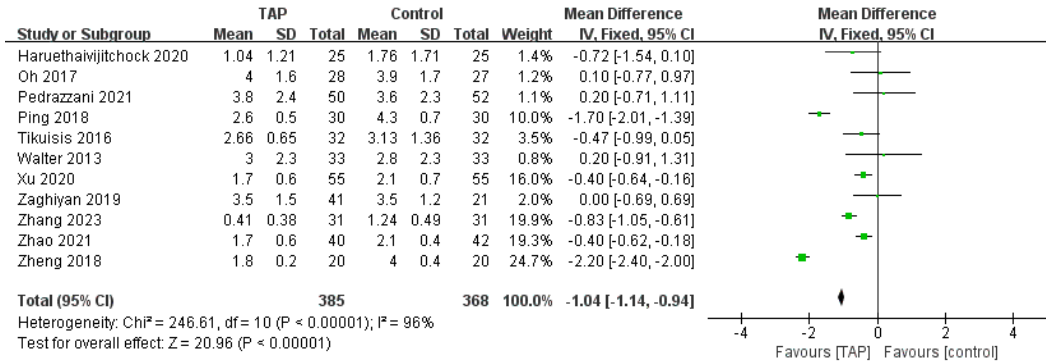


Supplement Fig. 11. Forest plots of (A) postoperative pain using the visual analogue scale (within 2 hours), (B) postoperative pain using the visual analogue scale (within 24 hours), (C) hospital stay, (D) postoperative nausea and vomit, and (E) prolonged postoperative ileus in transversus abdominis plane block versus conventional pain control method.

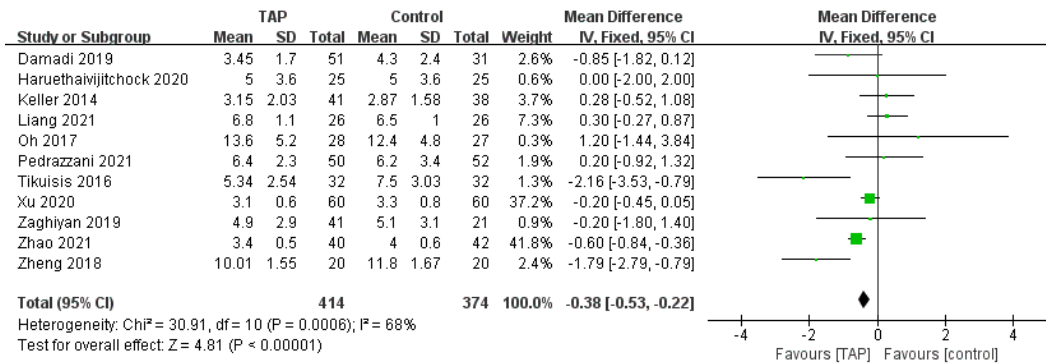
(A)



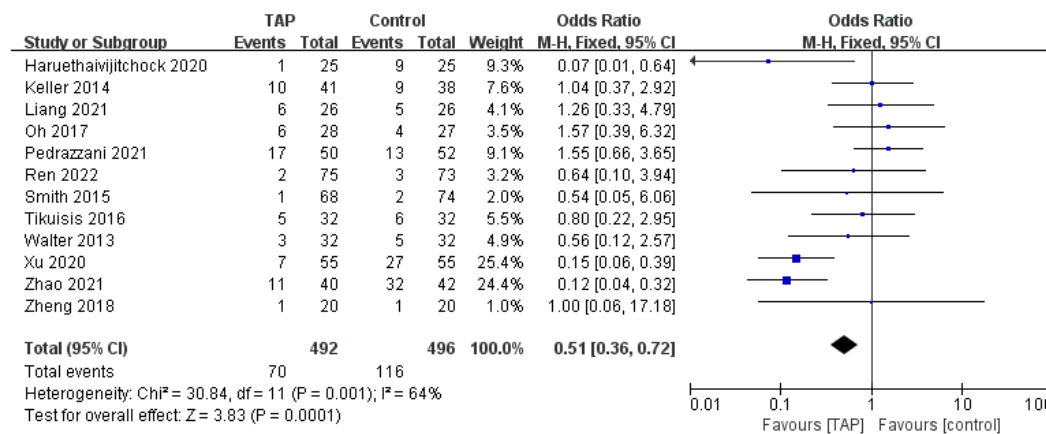
(B)



(C)



(D)



(E)

